

Reprinted from

SEPTEMBER/OCTOBER 2002

AESTHETIC SURGERY

JOURNAL

Low-Level Laser-Assisted Liposculpture; Clinical Report of 700 Cases

Rodrigo Neira, MD; and Clara Ortiz-Neira, MD



OFFICIAL PUBLICATION OF THE AMERICAN SOCIETY FOR AESTHETIC PLASTIC SURGERY
OFFICIAL ENGLISH-LANGUAGE JOURNAL OF THE BRAZILIAN SOCIETY OF PLASTIC SURGERY

www.mosby.com/aesthetic



Low-level Laser-assisted Liposculpture: Clinical Report of 700 Cases

Rodrigo Neira, MD; and Clara Ortiz-Neira, MD

Background: Suction-assisted lipoplasty has limitations, particularly in dealing with fibrous areas such as the back, sides, and male chest, or when secondary lipoplasty is performed.

Objective: The use of low-level laser-assisted lipoplasty was evaluated in a series of 700 cases.

Methods: After adequate infiltration was obtained in all targeted body areas, a 635-nm electric diode laser was applied to the targeted areas for 6 to 12 minutes, depending on the specific area, to liquefy the fat, which was extracted immediately after laser treatment.

Results: Excellent aesthetic results, including an improved silhouette contour, smooth abdominal surface, and good skin retraction, were obtained in 95% of cases.

Postoperative recovery was rapid, and complications were minimal.

Conclusions: Low-level laser-assisted lipoplasty can be a valuable adjunctive tool for the performance of lipoplasty. (Aesthetic Surg J 2002;22:451-455.)

Lipoplasty has become the most frequently performed aesthetic surgery procedure. However, suction-assisted lipoplasty has limitations, especially when dealing with fibrous areas such as the back, sides, and male chest, and when secondary liposuction is performed. In these cases, suction-assisted lipoplasty can produce inconsistent and even poor results.¹ These limitations led Zocchi to develop ultrasound-assisted lipoplasty in 1988.^{2,3}

Neira et al⁴⁻⁶ presented results obtained with 700 patients who had undergone low-level laser-assisted lipoplasty (the Neira 4L technique), in which energy from a 635-nm electric diode laser is applied to a specific body area for a period of 6 minutes. This procedure liquefies almost 100% of the targeted fat, making it easier to extract.⁷⁻¹⁰ Clinical results are, as a result, greatly improved.

Surgical Technique

Low-level laser lipoplasty was performed with the patient under sedation (fentanyl, midazolam) and conscious during the procedure. Patients were informed in advance that this technique is new and still under clinical study. With the written consent of the patients, photographs were taken before and after surgery.

The procedure consisted of traditional lipoplasty using the following technique. All body areas that were to be suctioned were infiltrated with a wetting solution consist-

Dr. Neira is a plastic surgeon in Cali, Colombia, and a member of the Colombian Society of Plastic, Aesthetic, Maxillofacial and Hand Surgery. Dr. Ortiz-Neira is a physician in Cali, Colombia.

Accepted for publication April 10, 2002.

Reprint requests: Rodrigo Neira, MD, Avenida 4 Oeste No. 5-274, Apt. 301B, Cali, Colombia.

Copyright © 2002 by The American Society for Aesthetic Plastic Surgery, Inc.

1090-820X/2002/\$35.00 + 0

70/1/128622

doi:10.1067/maj.2002.128622

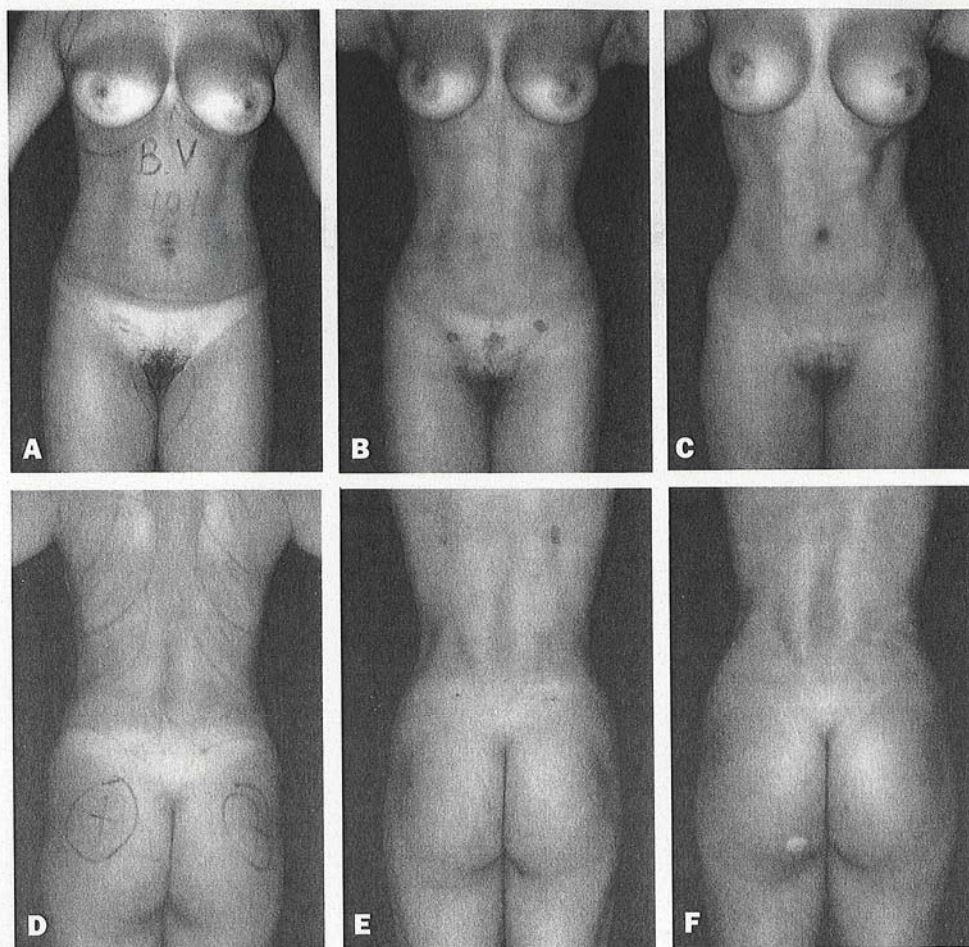


Figure 1. A, D, Preoperative views of an 18-year-old woman. B, E, Postoperative views 1 month after low-level laser-assisted lipoplasty. C, F, Postoperative views 14 months after lipoplasty.

ing of saline solution, 1000 mL; lidocaine 2%, 25 mL; adrenaline 1:1000 amp, 1 mL; and HCO_3Na 8.4%, 10 mL. After achieving adequate infiltration in all target areas, an external 635-nm electric diode laser with a 1-mm diameter and potency of 14 mV was applied for 6 minutes to the abdomen and thighs, and 10 to 12 minutes to the back, sides, and axillas, where the fat is harder to liquefy. The laser was manually programmed to move back and forth to cover each treatment area. The treatment areas were scanned with a digital scanning arm to make sure the surface was covered. The fat was then extracted with a 4-, 5-, or 6-mm cannula. The deep fat was immediately extracted, followed by the superficial fat. To reduce surgical time, while lipoplasty was being performed in one area, the laser was placed at the next area scheduled for treatment.

Postoperative Care

Postoperative pain was minimal, and controlled with

acetaminophen and nonsteroidal antiinflammatory drugs. Patients were followed up after operation at 24 hours, 48 hours, 72 hours, 8 days, 15 days, 30 days, 60 days, and 6 months.

Results

An average of 5 L of fat was extracted in each procedure. A satisfactory silhouette contour was achieved, and 95% of patients were satisfied with the results (Figures 1-3). Skin retraction was adequate. Patients experienced a minimum of postoperative pain and were able to return to normal activities within 72 hours.

Complications

Asymmetries occurred in less than 3% of the procedures. Hyperpigmentation occurred in 0.1% of procedures. There were 2 cases of cellulitis, one caused by *Escherichia coli* and the other by *Streptococcus sp.* The

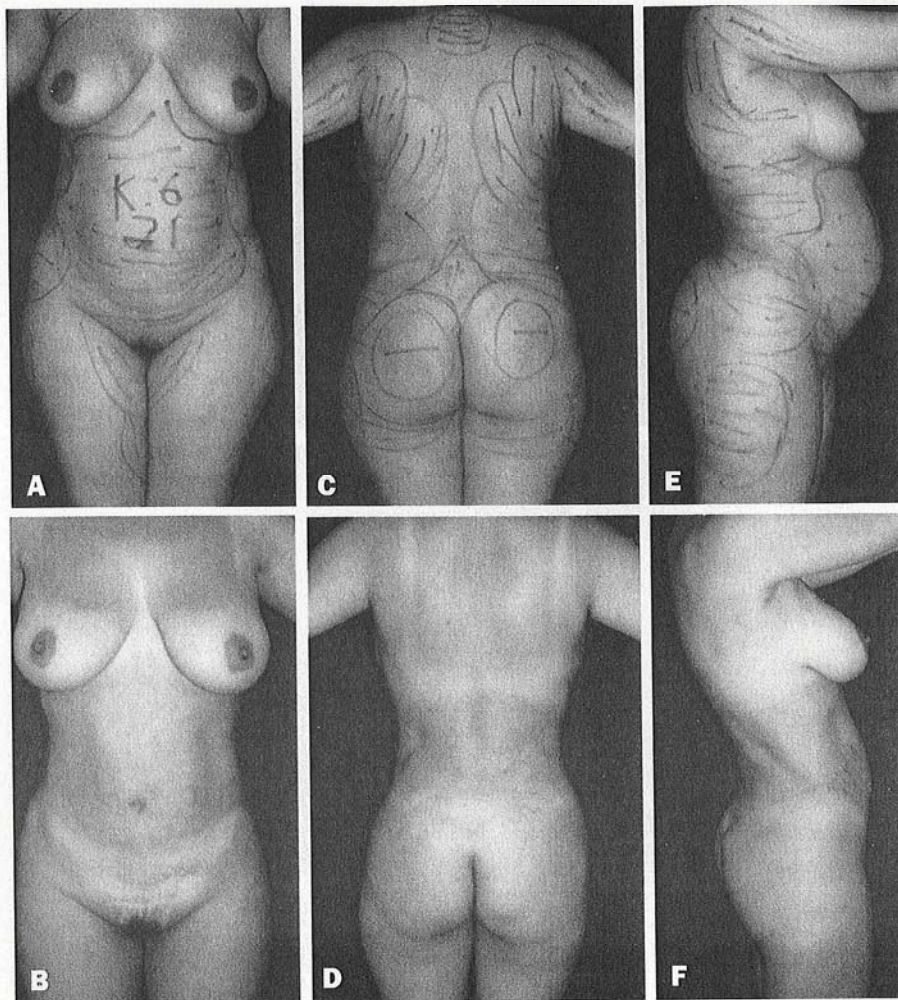


Figure 2. A, C, E, Preoperative views of a 31-year-old woman. B, D, F, Postoperative views 9 months after low-level laser-assisted lipoplasty. Note the smooth abdominal surface and good skin retraction.

incidence of hematomas, ecchymoses, and skin lesions was minimal (5%). Fluid collection, or seromas, in 40% of the patients resolved after syringe extraction (maximum of 3 aspirations) during the first 2 weeks after operation. Very little postsurgical edema was noted. None of the patients was hospitalized, no cases of skin burn occurred, and no cases of skin necrosis occurred, even in patients undergoing megalipoplasty.

Discussion

Low-level laser lipoplasty is a new technique that provides intraoperative and postoperative benefits to both the surgeon and the patient. The basic science of the procedure has been reported previously.¹³ During operation, because the fat is liquefied, its extraction is facilitated, particularly in fibrous areas such as the back and sides. Consequently, less physical effort is required of

the surgeon. In addition, a flatter and more uniform surface is obtained. Because the time needed to extract the fat is reduced, there is less surgical trauma and less postoperative edema. The incidence of sacral fluid collection in my practice was reduced from 70% using traditional lipoplasty to 40% using low-level laser lipoplasty. There is very little bleeding, eliminating the need for transfusions. The patient is not exposed to skin burns. Postoperative pain is minimal, and patients are able to return to work quickly.

Conclusion

Low-level laser-assisted lipoplasty is a new technique that offers rapid postoperative recovery and highly satisfactory aesthetic results. The technique is easy to learn and to apply and can be a valuable tool for surgeons who perform lipoplasty procedures. ■

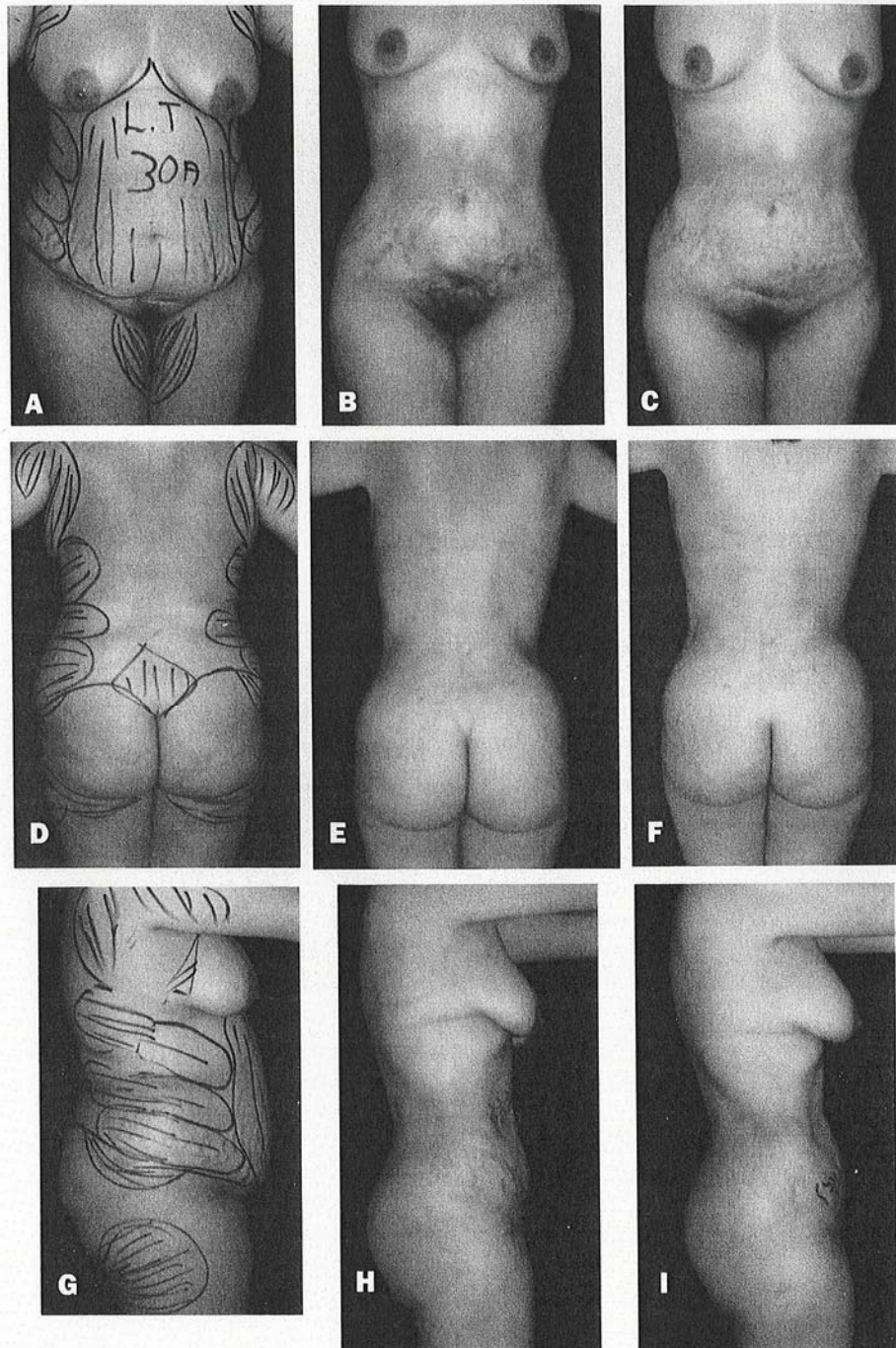


Figure 3. A, D, G, Preoperative views of a 30-year-old woman. B, E, H, Postoperative views 3 months after low-level laser-assisted lipoplasty. C, F, I, Postoperative views 8 months after lipoplasty. Note the smooth abdominal surface and good skin retraction.

References

1. Rohrich R, Beran S, Kenkel J. *Ultrasound-Assisted Liposuction*. St. Louis: Quality Medical Publishing; 1998.
2. Zocchi M. Perspective in lipoplasty: the ultrasonic-assisted lipectomy (UAL). Presented at the French Society of Aesthetic Surgery; Paris, France; May 1988.
3. Zocchi M. Ultrasonic liposculpturing. *Aesthetic Plast Surg* 1992; 16:287-298.
4. Neira R, Arroyabe A, Solarte E, Gutierrez O, Isaza C. Low level laser assisted liposuction, a new technique. Presented at the 70th Annual Scientific Meeting of the American Society of Plastic Surgeons/ Plastic Surgery Educational Fund; Orlando, Fla; Nov 3-7 2001.

5. Neira R, Arroyabe A, Solarte E, Gutierrez O, Isaza C. Low level laser assisted lipoplasty, a new technique. Presented at the Centro American and Caribbean Plastic Surgery Meeting; Dominican Republic; July 11, 2001.
6. Neira R, Arroyabe A, Isaza C, Gutierrez O, Solarte E, Ortiz C. Fat liquefaction: effect from low level laser energy. Presented at the Society of Latin American Plastic Surgeons Meeting; Orlando, Fla; Nov 5, 2001.
7. Neira R, Ortiz C, Arroyave J, Solarte E. Laser irradiation effect in aesthetic surgery. Presented at VII Encuentro Nacional de Optica, Universidad del Quindio, Armenia, Colombia, September 25-29, 2000.
8. Neira R, Arroyave J, Reyes A, Solarte E. Laser irradiation effect in adipocyte dilutions. Presented at the Congreso Nacional de Física Universidad Nacional Manizales, Colombia, September 24-29, 2001.
9. Neira R, Rebolledo AF, Reyes MA, et al. Defraction and dispersion of coherent light in adipose tissue. Presented at the Congreso Nacional de Física Universidad Nacional Manizales, Colombia, September 24-29, 2001.
10. Neira R, Rebolledo AF, Montoya JA, et al. Coherent light dispersion in adipose tissue samples. Presented at the Congreso Nacional de Física Universidad Nacional Manizales, Colombia, September 24-29, 2001.
11. Rohrich RJ, Beran SJ, Kenkel JM. Extending the role of liposuction in body contouring with ultrasound-assisted liposuction. *Plast Reconstr Surg* 1998;101:1090.
12. Neira R, Isaza C, Gutierrez O, Criolle W, Ortiz C. In vitro human culture of adipocytes. Presented at the Bolivarian Meeting of Plastic and Reconstructive Surgery; Lima, Peru; October 2001.
13. Neira R, Arroyave J, Ramirez H, et al. Fat liquefaction: effect of low-level laser energy on adipose tissue. *Plast Reconstr Surg* 2002;110:912-921.